

See discussions, stats, and author profiles for this publication at: <https://www.researchgate.net/publication/267641007>

Male-to-female vaginoplasty: Preecha's surgical technique

Article in *Journal of Plastic Surgery and Hand Surgery* · October 2014

DOI: 10.3109/2000656X.2014.967253

CITATIONS

17

READS

127,357

6 authors, including:



Gennaro Selvaggi

Sahlgrenska University Hospital

51 PUBLICATIONS 1,106 CITATIONS

SEE PROFILE

Some of the authors of this publication are also working on these related projects:



Gender Affirmation Surgery [View project](#)

ORIGINAL ARTICLE

Male-to-female vaginoplasty: Preecha's surgical technique

Burin Wangjiraniran¹, Gennaro Selvaggi², Prayuth Chokrungruanont^{1,3}, Sirachai Jindarak^{1,3}, Sutin Khobunsongserm¹ & Preecha Tiewtranon¹

¹Preecha Aesthetic Institute (PAI), Bangkok, Thailand, ²Department of Plastic Surgery, Institute of Clinical Sciences, Sahlgrenska Academy, University of Gothenburg, at Sahlgrenska University Hospital, Gothenburg, Sweden and ³Division of Plastic & Reconstructive Surgery, Department of Surgery, Faculty of Medicine, Chulalongkorn University, Bangkok, Thailand

Abstract

The inverted peno-scrotal flap is considered the standard technique for vaginoplasty in male-to-female transsexuals. Nowadays, great importance is also given by patients to the reconstruction of the clitoro-labial complex; this is also reconstructed with tissue coming from glans penis, penile skin envelop and scrotal skin. Since the first sex reassignment surgery for biological males performed in Thailand in 1975, Dr Preecha and his team developed the surgical technique for vaginoplasty; many refinements have been introduced during the past 40 years, with nearly 3000 patients operated on. The scope of this paper is to present the surgical technique currently in use for vaginoplasty and clitoro-labioplasty and the refinements introduced at the Chulalongkorn University and at the Preecha Aesthetic Institute, Bangkok, Thailand. These refinements consist of cavity dissection with blunt technique, the use of skin graft in addition to the penile flap, shaping of the clitoris complex from penis glans and clitoral hood, and the use of the urethral mucosa to line the anterior fourchette of the neo-vagina. With the refinements introduced, it has been possible to achieve a result that is very close to the biological female genitalia.

Key Words: gender dysphoria, gender reassignment surgery, sex reassignment surgery, surgical technique, vaginoplasty, male-to-female transsexualism

Background

Gender dysphoria

The delineation of conditions involving Gender Dysphoria started in Germany in the 19th century [1], but it was Benjamin's [2] publication "The transsexual phenomenon" on the subject in 1966 that led to the widespread use of the term transsexualism.

As currently defined in DSM V, Gender Dysphoria communicates the emotional distress that can result from "a marked incongruence between one's experienced/expressed gender and assigned gender" [3].

In Europe, the most recent epidemiological study and review about transsexualism reports prevalence ranging from 1:11,900–1:45,000 for male-to-female persons (MTF) and 1:30,400–1:200,000 for female-to-male (FTM) persons [4], with an increasing number of patients seeking assistance in the recent years [5].

Particularly, in The Netherlands the prevalence of people wishing to receive hormonal or surgical therapy because of the incongruent gender identity is 0.6% for biological males and 0.2% for biological females [6].

In Asia, a recent report calculated the rates in Japan to be 1:25,000 for male-to-female and 1:12,000 for female-to-male [7]. To date, there are no reliable epidemiological studies about the prevalence of gender dysphoria in Thailand.

Still, we expect in Thailand a much higher incidence of transsexualism compared to the data reported in the world literature, since it is possible to observe and find transsexual

people in any public place such as school, universities, and any working place [8].

Male-to-female vaginoplasty

As affirmed by Karim et al. [9], the aim of genital reassignment surgery in male-to-female transsexuals is to create a perineo-genital complex as feminine in appearance and function as possible and free of poorly healed areas, scars and neuromas. The urethra should be shortened in such a way that the direction of the urinary stream is downward in the sitting position and it should be free of stenosis or fistulas. The neovagina should, ideally, be lined with moist, elastic and hairless epithelium. Its depth should be at least 10 cm and its diameter 30 mm. The sensation should be sufficient to provide satisfactory erogenous stimulus during sexual intercourse. Ideally, all these requirements should be met without major surgical intervention necessitating long and distressful postoperative treatment, and addressing them should not create new lesions or donor area malfunction.

Abraham reported the first case of Sex Reassignment Surgery (SRS) as early as 1931 [10]. Later, many reports followed, demonstrating an evolution of techniques. Orchidectomy, amputation of the penis, creation of the neovaginal cavity, lining of this cavity and reconstruction of a urethral meatus and, finally, construction of the labia and clitoris may be identified as the five major steps in all of these techniques [9,11]. To date, the penile-scrotal skin flap technique is considered the state of the art for vaginoplasty in male-to-female transsexuals [11].

To date, surgeons performing vaginoplasty for MTF transsexuals are still aiming to improve the technique with the aim of: increasing the neovaginal length and width, preventing complications, and finally ameliorating the cosmetic outcome [12].

Sex reassignment surgery in Thailand

Dr Preecha Tiewtranon and Dr Prakob Thongpeaw performed the first male-to-female sex reassignment surgery in Thailand in 1975. A parallel manuscript [9] explains the development of GRS in Thailand, in terms of social attitude, epidemiology, surgical patients' profile, law and regulation, religion, patients' path from psychiatric assessment to surgery, and gender surgeries.

To date, there are more than 100 reputable surgeons in Thailand who are able to perform a vaginoplasty in MTF transsexuals. Since 1983, in fact, Dr Preecha has trained nearly all these surgeons at Chulalongkorn University Hospital in Bangkok. During these years, Dr Preecha and his team have developed and implemented many surgical refinements, and operated on ~ 3000 patients.

The scope of this paper is to illustrate Dr Preecha's surgical technique and give emphasis to the refinements which can stand out in the final outcome. Finally, we attempt to discuss advantages and disadvantages of Preecha's approach and results compared to the outcomes from other groups, in spite of the lack of long-term follow-ups within the scientific literature.

However, it is not the purpose of this manuscript to report on the long-term outcomes of Preecha's series.

Materials and methods

In the period 1975–2013, Preecha's group (Bangkok, Thailand) performed nearly 3000 vaginoplasties in male-to-female transsexuals.

In the present manuscript we describe in details the surgical technique currently in use by the same group (Chulalongkorn University and "Preecha Aesthetic Institute" (PAI), Bangkok). Preecha's technique is comprised of several surgical refinements added during the past 39 years of practice by Dr Preecha and his team colleagues.

The surgical technique as presented in this manuscript has also been used in a series of 395 patients, operated on in the period 2009–2013; immediate postoperative outcomes of this series of patients are shown.

It is out of the scope of this paper to present and discuss long-term results.

Preoperative preparation

The patient is informed to stop hormonal therapy 3–4 weeks before the surgery. The bowel is prepared the night before, at home or at the hotel, with Sodium phosphate oral solution 45 ml, two doses in 4 hours. Clexane is given only in the case of history of previous DVT. A pumping system to the legs is used during the surgery and, during day 1, the operation is longer than 4 hours. The patient can choose between general anaesthesia or spinal anaesthesia. Augmentin is given during the hospital stay.

Patient position

The patient is in anti-Trendelenburg position (30°) for the entire length of the surgery.

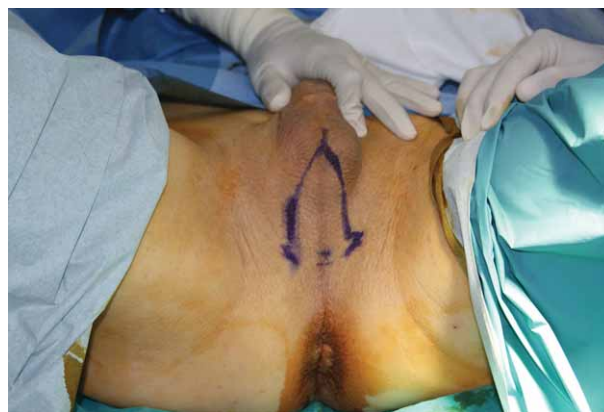

Figure 1. Preoperative drawing of the scrotal flap.

Preecha's surgical technique

The skin is not infiltrated with anaesthetic solution, in order not to jeopardise vascularisation. A scrotal flap is harvested (see Figure 1). Its base is ~ 4 cm higher than the anus and its length goes up to the base of the penis.

Following the flap dissection, the bulbo-cavernosus muscles are excised. The cavity is then made between the prostate wall and the rectus. In order to perform this step, the surgeon proceeds, alternating the use of the electro-cautery and the metal suction to make the cavity. At this stage, the operator fingers are pushing down the anterior wall of the rectus, while the contra-lateral hand holds either metal suction (Figure 2) or cautery (Figure 3). A Diver's retractor is pulled up the falling urethra (Figures 2 and 3). Only for the final part of the dissection is a stent inserted into the anus. At this point the patient's bed is tilted to 45°, the stent is removed from the rectum and another stent is inserted into the perineal cavity to make it deeper (Figure 4).

Usually, the cavity is variable between 4–6 inches. However, the penile skin is not enough for covering of the entire cavity.

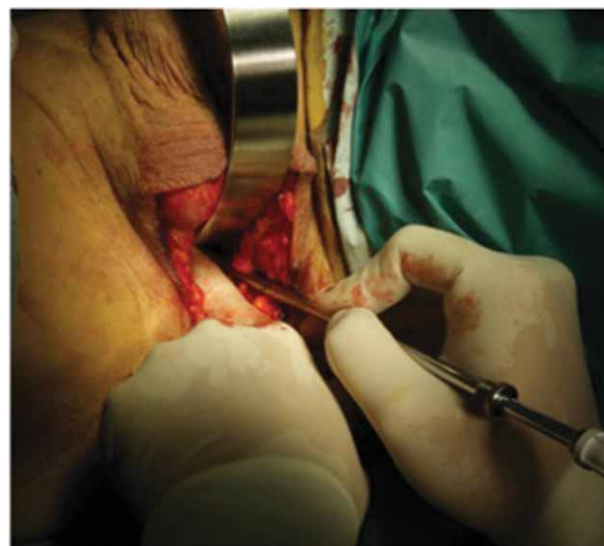

Figure 2. Cavity dissection, the operator fingers are pushing down the anterior wall of the rectus, while the contra-lateral hand holds the metal suction. A Diver's retractor is pulling up the falling urethra.

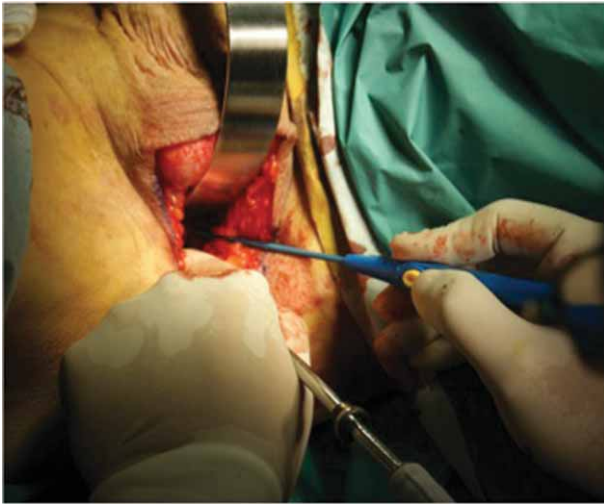


Figure 3. Cavity dissection, the operator fingers are pushing down the anterior wall of the rectus, while the contra-lateral hand holds the cautery. A Diver's retractor is pulling up the falling urethra.

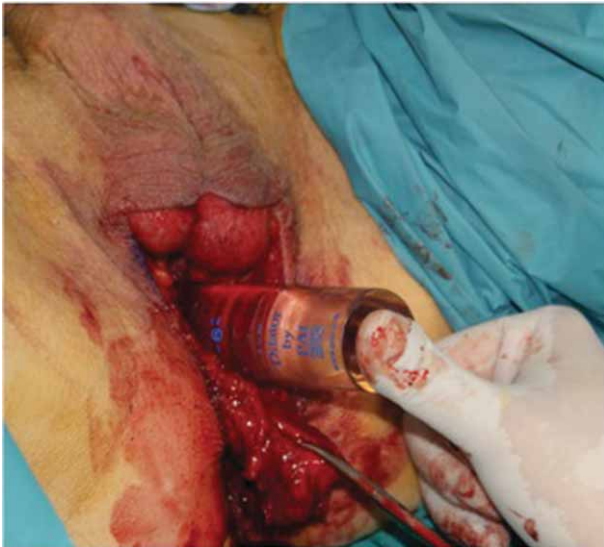

Figure 4. A stent is inserted into the perineal space to make the cavity deeper.

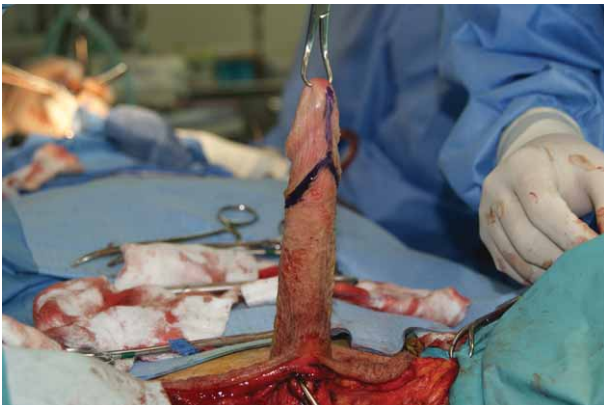

Figure 5. Marking on the inferior surface of the penis, showing the amount of prepuce skin incorporated into the glans flap.

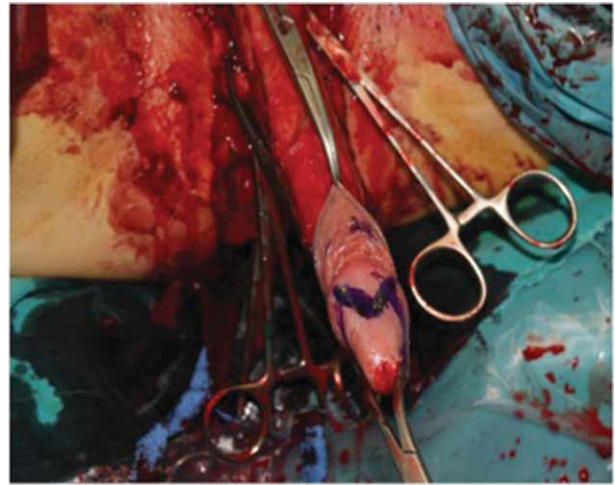


Figure 6. The glans is incised in a M-shape.

Scrotal skin is usually harvested as a full-thickness skin graft. The penile skin is then opened posteriorly with scissors.

The patient is then put flat. Corpora cavernosa are dissected, testicles ligated and excised. A catheter is inserted to guide the urethral dissection and the resection of the corpus spongiosum. Remnants of corpus spongiosum are sutured with 4/0 chromic cutgut. The glans is then designed (Figure 5) and the penile skin is removed.

The corpora cavernosa are ligated at base with a string, and the dissection of the glans flap is started. The glans is incised in a M-shape (Figure 6), with abundant prepuce skin around (Figures 5 and 7).

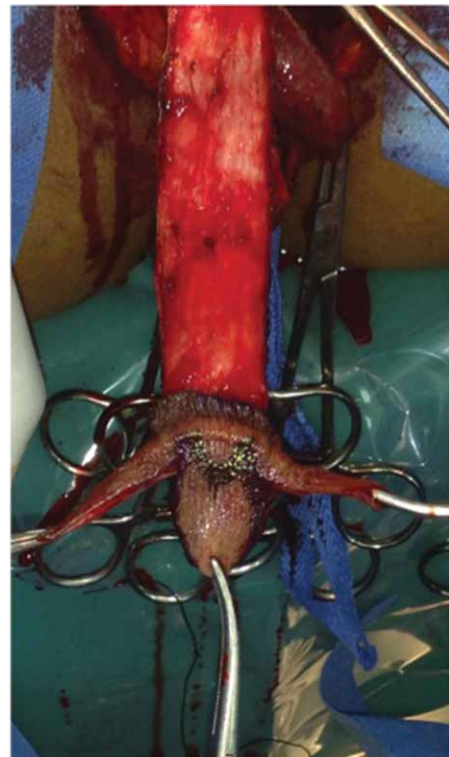

Figure 7. Abundant prepuce skin is harvested from the superior surface of the penis, and incorporated into the glans flap.

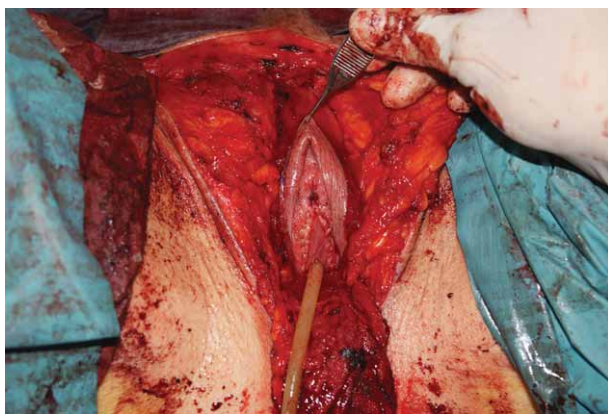


Figure 8. The urethra is spatulated, its tunica muscularis removed and the mucosa layer is fixed laterally and inferiorly to the clitoris.

The pedicle of the glans flap is incorporating the tunica albuginea. The inferior wall of the tunica albuginea, incorporated into the glans pedicle, is denuded from the residual corpora cavernosa attached to it. The rest of the corpora cavernosa (rest of the tunica albuginea and internal blood system) is removed from its base and legated.

The lateral flaps of the M-glans are sutured in the middle, in front of the body of the glans' tip, with 5/0 PDS (see Figure 8). If needed, at this stage a further reduction of the glans tip can be performed. A space is then made on the pubis symphysis and the pedicled glans, bent on itself, is secured on it.

The urethra is spatulated, its tunica muscularis removed and the mucosa layer is fixed laterally and inferiorly to the clitoris (see Figure 8).

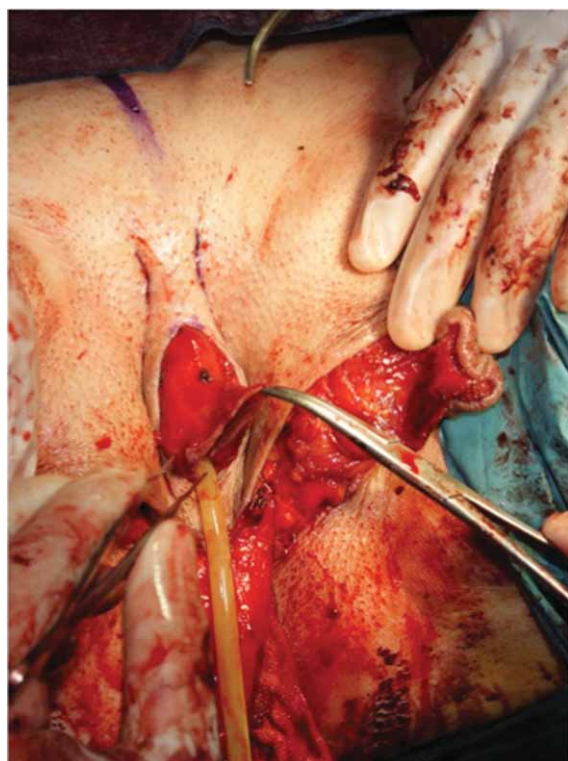


Figure 9. Six small superficial incisions (epidermis only) (three per side) are made higher to the clitoris, and 4/0 PDS stitches are passed from side to side to bottom out the skin so as to resemble the bulging of the corpora cavernosa of the clitoris.

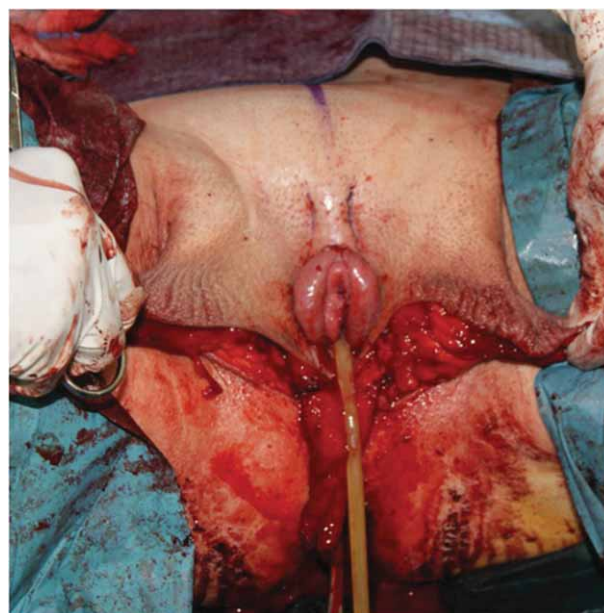


Figure 10. Close-up of the reconstructed clitoris head, clitoral hood, and corpora cavernosa of the clitoris.

The scrotal flap is then thinned. A stitch might be put between the scrotal flap and the rectum, to fix its position and prevent too much scrotal show. The penile flap is inserted into the cavity. Six small superficial incisions (epidermis only) (three per side) are made higher to the clitoris and 4/0 PDS stitches are passed from side to side to bottom out the skin so to resemble the bulging of the corpora cavernosa of the clitoris (see Figure 9).

Figure 10 shows the final result of the reconstructed clitoris/clitoral hood/clitoris corpora at this point of the procedure. The labia are shaped simply, excising the scrotal skin (see Figure 11), which is used as full thickness skin graft, attached to the penile skin flap and used to cover the deepest part of the cavity. The skin graft is sutured with 4/0 chromic catgut.

The suture between scrotal flap and rectum is now legated. A suction drain is used, and the patient is catheterised. Surgicel is positioned on the clitoris, covered with a swab with Jelonet around, and fixed with 4/0 PDS.

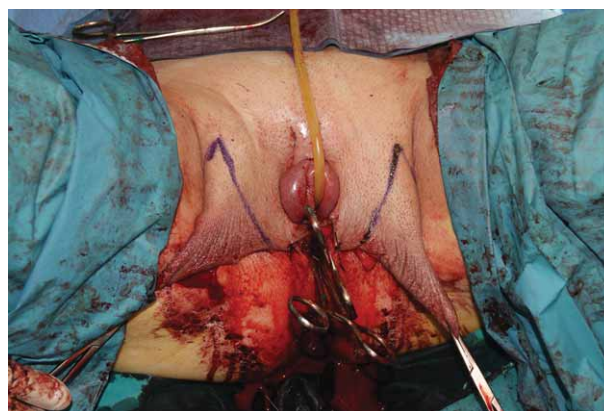


Figure 11. The labia are shaped, simply excising the scrotal skin: this is then used as a full thickness skin graft, and attached to the penile skin flap.

Figure 12 shows the penile skin envelope and the skin graft from the scrotum. The skin graft is simply tabularised and attached as a *cul-de-sac* distally to the penile skin shaft.

Figure 13 shows the immediate post-operative result: a condom filled with Betadine gauze is inserted into the constructed vagina.

Figure 14 shows an example of a long-term follow-up (over 1 year).

Dressing

A speculum is used to help with insertion of a condom filled with swabs soaked into betadine. This has been the preferred vaginal packing since the beginning. Jelonet gauze is put on the labia (Figure 13).

Postoperative management

The patient stays in bed for a couple of days. The condom with swabs is removed on day 4 after surgery, together with the drain. The cavity is washed with Betadine. The catheter is removed on day 5 in the morning. If the patient is able to urinate, discharge happens on the same day in the evening.

Results

Peri-operative complications of the series of 395 patients operated on with the current technique are presented in Table I. Figures 13 and 14 show, respectively, immediate and long-term results of the surgical technique described.

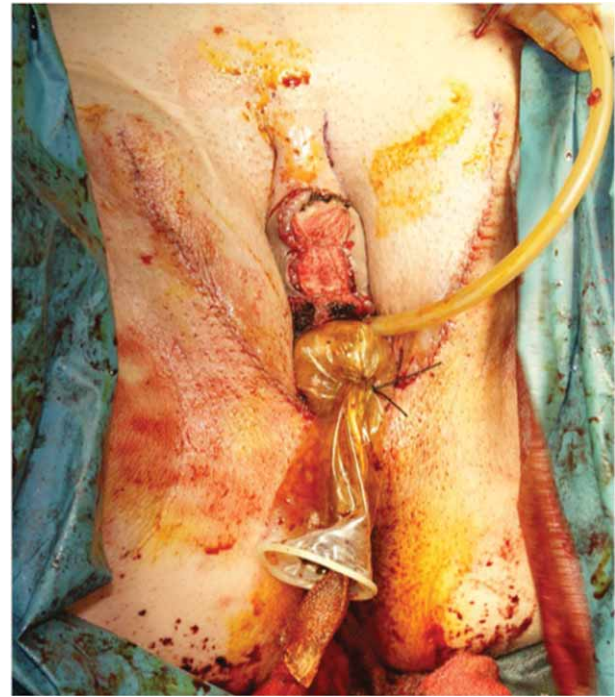


Figure 13. Immediate postoperative result: a condom filled with Betadine gauze is inserted into the constructed vagina.

Discussion

The surgical technique for vaginoplasty and clitoro-labioplasty used at the Chulalongkorn University and at the PAI in Bangkok is the evolution of several refinements implemented to the original inversion peno-scrotal technique.

Some of the steps of the procedure (e.g. scrotal flap to break the introitus [11], spatulating of the urethra [13,14], glans pedicle dissection [15], orchidectomy, subtotal excision of the corpus spongiosum [11], labia reshaping) are similar to any other refinement reported in the modern scientific literature [11,16].

Similarly, the patient's management (e.g. pre-operative preparation, vaginal packing, vaginal dilation post-discharge) used at the Chulalongkorn University and at the PAI does not differ from what has been previously reported [11,16].

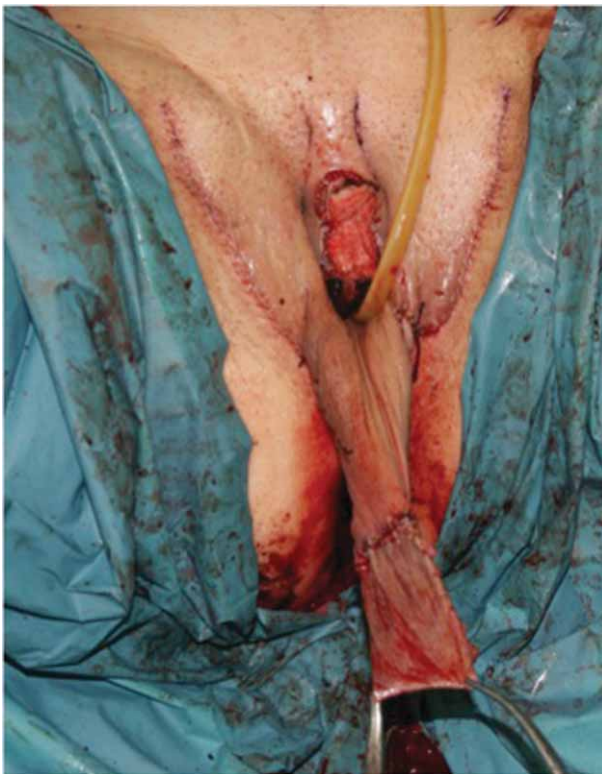

Figure 12: Penile skin envelope, and skin graft (from scrotum) tabularised and sutured as a cul-de-sac to the skin envelope. The complex penile skin/skin graft has been everted, before the final inversion (into the cavity) and packing.



Figure 14. Over 1 year long-term follow-up.

Table I. Patients operated on in the period 2009–2013 with the current surgical technique, and peri-operative complications.

Surgical time	3 hours (2.5–4)
Total number of patients operated on?	395
Bleeding requiring reoperation	2 cases
Blood transfusion	10 (2.5%)
Infection (minor)	4%
Recto-vagina Fistula	0
Clitoral necrosis	0
Temporary urinary complications obstruction at 1–2 weeks postsurgery	1.5%
Complete Skin graft loss	1 case
Partial skin graft loss	1.5%
Flap prolapse	1 case

Preecha's team refinements consist of: (1) cavity dissection with blunt technique; (2) the use of skin graft in addition to the penile flap; (3) shaping of the clitoris with abundant prepuccial foreskin; and (4) urethra mucosa to line the anterior fourchette.

Table II shows the evolution of the technique (introduction of the refinements) and the impact on the outcomes.

Cavity dissection

Generally, the cavity can be made using a sharp [17] or a blunt dissection [12,17]. Preecha's team prefers the use of alternating electro-cautery and metal suction for the first part, and continuing blunt with a dilator for the final part. In this way, the cavity is made nearly with no blood loss or immediate blood aspiration and coagulation of any new bleeding vessel.

The way to move the rectum away from the dissection plane is similar to any other blunt approach. There is no published follow-up that gives results or shows an advantage of one approach compared to the others.

Skin graft

Many Thai patients are presenting with a short penis; many patients from Arabic countries are circumcised; many patients from western countries demand a deep vagina (deeper than 14 cm): as a consequence, the use of skin graft has become very common at our centre. Still, when there is abundant penile skin, the vagina is solely lined with penile skin. The preferred skin graft used is a full thickness from the scrotum.

In the literature, there is no published follow-up that gives results, showing an advantage and eventually providing evidence on the use of the skin graft vs scrotal flap vs conventional penile inversion technique. Nevertheless, it is common practice

in many centres [11,17] to use an additional graft or flap when the amount of available penile skin is considered inadequate to line the new vaginal cavity to provide adequate vaginal depth.

When preparing the graft, care is taken in removing all the hair follicles. The major advantages of using a skin graft consists of: (1) allowing one to line deep vaginas with an adequate amount of skin; and (2) allowing prepuccial skin to be used for reconstruction of the labia minora/clitoral hood. Differently from other centres' approaches [11,12,17], our method has the advantage that it does not require a preoperative epilation.

The major disadvantage claimed in the literature consists of the risk of graft loss. However, it is our opinion that, even in the case the graft is lost, the vagina would still not result in being shorter than the case were a graft had not been used.

A long-term follow up is necessary to assess the vaginal depth immediately after surgery and at long-term. Indeed, the dilation regiment used by the patient after surgery constitutes an extra bias to be evaluated.

Differently from other authors [17], we do not use a large scrotal flap, and, therefore, patient epilation before surgery is either not necessary, or limited to the tip of the small scrotal flap in some cases. Avoiding a large scrotal flap also means reducing the risk of prolapse [17].

Possibly, as also affirmed by other authors [12], the way the skin is lined and held into the new cavity (i.e. by a condom filled up with swabs, and left in place for 5 days) is key to prevent prolapse, even without the use of additional sutures [17,18].

Shaping of the clitoris

Because of the use of skin grafts, more prepuccial skin becomes available to be used for the creation of the labia minora and clitoral hood. Dissecting the tip of the glans "en-block" with its prepuccial skin better resembles the natural anatomy of the clitoris/clitoral hood complex.

Using the bottoming out stitches to create the external appearance of the body of the clitoris is easy to perform. Some fat tissue needs to be left under the skin flap otherwise the plications achieved will be flattened in the long-term.

Indeed, a long-term follow-up evaluation is required. Nevertheless, in the literature there is no assessment of the patients' satisfaction with the long-term cosmetic outcomes of this procedure.

Urethra to line the anterior fourchette

As in other reports [11,13,14,17,19], the urethra is spatulated; however, the urethra is not simply left in place, neither is it used

Table II. Evolution of the Preecha's surgical technique.

Year	Technique/refinement	Effect
1975	Primitive inverted peno-scrotal flap	
1983	Posterior urethral flap	To prevent urethra stenosis To give some mucosa tissue to vaginal introitus
1990	Total resection of the corpus spongiosum	To allow penetration without swelling during sexual arousal
1999	Surgicel onto urethra clitoris	To prevent bleeding
2000	Bottoming out suture on the top of clitoris	Appearance of the clitoral body
2003	Prepuccial skin	Reconstruction of the clitoral hood
2003	M-shaped glans flap	Shaping of the clitoris
2005	Perineal stitch to fix the scrotal flap to the rectal wall	Prevention of (minor) scrotal flap prolapse

as a flap to constitute part of the vaginal wall [13]. In fact, in our technique the tunica muscularis of the urethra is removed, and the mucosa layer is used in a large amount to line the anterior vaginal fourchette, covering the entire area laterally and inferiorly to the clitoris. In this way, we avoid completely the fake appearance of cutaneous tissue in between the urethral meatus and the clitoris, often seen in old techniques. Again, this is a descriptive outcome resulting from one detail of our surgical technique; the evaluation of the anterior vaginal fourchette constitutes a detail that has never been assessed by previous authors.

Comparison of Preecha's outcomes vs the literature

The details introduced with our technique mainly have an impact, and make a difference to the cosmetic outcome, if comparing our standard 1-year result to the results presented in the literature.

In regards to the functional outcomes related to quality-of-life or other patient reported experience measurements, these have very rarely been evaluated on a large series of patients [20–24]; still, it is not within the scope of this manuscript to assess long-term functionality or quality-of-life of this group of patients; nevertheless, our surgical details do not propose any major change, apart the cosmetic refinements, which would justify a better or worse scoring in functional measurements, compared to techniques from other authors. Similarly, peri-operative complications do not appear to be different from the literature [16,17,25,26].

Conclusion

Since the first sex reassignment surgery for biological males performed in Thailand in 1975, Dr Preecha and his team developed their surgical technique for vaginoplasty and clitoro-labioplasty. During the years, many refinements that progressively ameliorated the results of this procedure were introduced. Immediate post-operative results of a series of 395 cases operated in the period 2009–2013 with the technique hereby described are presented. The surgical refinements described led to them achieving a result that is very close to the biological female genitalia cosmetically and functionally.

In future, further improvements are needed to provide the vagina with more mucosa-like tissue, and to ease the postoperative dilation regimen.

Declaration of interest: The authors report no conflicts of interest. The authors alone are responsible for the content and writing of the paper.

References

- [1] Eicher W. Transsexualismus. G. Fischer Verlag, Stuttgart, Jena, New York; 1992.
- [2] Benjamin H. The transsexual phenomenon. Julian Press Inc; New York; 1966.
- [3] American Psychiatric Association. Diagnostic and statistical manual of mental disorders. 5th edition. American Psychiatric Publishing; Arlington, VA: 2013. p 5–25.

- [4] De Cuypere G, Van Hemelrijck M, Michel A, et al. Prevalence and demography of transsexualism in Belgium. *Eur Psychiatry* 2007;22:137–41.
- [5] Reed B, Rhodes S, Schofield P, Wylie K. Gender variance in the UK: prevalence, incidence, growth and geographic distribution. GIRES, Ashted, Surrey; 2009. Available from <http://www.gires.org.uk/assets/Medpro-Assets/GenderVarianceUK-report.pdf>. Accessed 28 March 2011.
- [6] Kuypers L, Wijnen C. Gender identities and gender dysphoria in the Netherlands. *Arch Sex Behav* 2013;43:377–85.
- [7] Baba T, Endo T, Ikeda K, et al. Distinctive features of female-to-male transsexualism and prevalence of gender identity disorder in Japan. *J Sex Med* 2011;8:1686–93.
- [8] Chokrungravanont P, Selvaggi G, Jindarak S, et al. The development of sex reassignment in Thailand: a social perspective. *SciWorldJournal* 2014;2014:182981.
- [9] Karim RB, Hage JJ, Mulder JW. Neovaginoplasty in male transsexuals: review of surgical techniques and recommendations regarding their eligibility. *Ann Plast Surg* 1996;37:669–75.
- [10] Abraham F. Genitalumwandlung an zwei männlichen transvestiten. *Sexwiss Sexpol* 1931;18:223–226.
- [11] Selvaggi G, Ceulemans P, De Cuypere G, et al. Gender identity disorder: general overview and surgical treatment for vaginoplasty in male-to-female transsexuals. *Plast Reconstr Surg* 2005;116:135e–45e.
- [12] Wroblewski P, Gustafsson J, Selvaggi G. Sex reassignment surgery for transsexuals. *Curr Opin Endocrinol Diabetes Obes* 2013;20:570–4.
- [13] Perovic SV, Stanojevic DS, Djordjevic ML. Vaginoplasty in male transsexuals using penile skin and a urethral flap. *BJU Int* 2000;86:843–50.
- [14] Amend B, Seibold J, Toomey P, et al. Surgical reconstruction for male-to-female sex reassignment. *Eur Urol* 2013;64:141–9.
- [15] Eldh J. Construction of a neovagina with preservation of the glans penis as a clitoris in male transsexuals. *Plast Reconstr Surg* 1993;91:895–903.
- [16] Karim RB, Hage JJ, Bouman FG, et al. Refinements of pre, intra, and post-operative care to prevent complications of vaginoplasty in male transsexuals. *Ann Plast Surg* 1995;35:279–84.
- [17] Selvaggi G, Bellringer J. Gender reassignment surgery: an overview. *Nat Rev Urol* 2011;8:274–82.
- [18] Stanojevic DS, Djordjevic ML, Milosevic A, et al. Sacrospinous ligament fixation for neovaginal prolapse prevention in male-to-female surgery. *Urology* 2007;70:767–71.
- [19] Trombetta C, Liguori G, Benvenuto S, et al. Neo-urethroclitoroplasty according to Petrovic. *Urologia* 2011;78:267–73.
- [20] Selvaggi G, Monstrey S, Ceulemans P, et al. Genital sensitivity after sex reassignment surgery. *Ann Plast Surg* 2007;58:427–33.
- [21] Hoebeke P, Selvaggi G, Ceulemans P, et al. Impact of sex reassignment surgery on lower urinary tract function. *Eur Urol* 2005;47:398–402.
- [22] De Cuypere G, T'Sjoen G, Beerten R, et al. Sexual and physical health after sex reassignment surgery. *Arch Sex Behav* 2005;35:679–90.
- [23] De Cuypere G, Elaut E, Heylens G, et al. Long-term follow-up: psychosocial outcomes of Belgian transsexuals after sex reassignment surgery. *Sexologies* 2006;15:126–33.
- [24] Weyers S, Elaut E, De Sutter P, et al. Long-term assessment of the physical, mental, and sexual health among transsexual women. *J Sex Med* 2009;6:752–60.
- [25] Hage JJ, Goedkoop AY, Karim RB, Kanhai RC. Secondary corrections of the vulva in male-to-female transsexuals. *Plast Reconstr Surg* 2000;106:350–9.
- [26] Sutcliffe PA, Dixon S, Akehurst RL, et al. Evaluation of surgical procedures for sex reassignment: a systematic review. *J Plast Reconstr Aesthet Surg* 2009;62:294–306.